



VETERINARY
ASSOCIATES
Equine
AND
Farm
LIMITED

12 SIM ROAD, KARAKA
POSTAL ADDRESS
PO BOX 135 DRURY 2247
PHONE: (09) 294 7307
FAX (09) 294 7323
vets@vetassociates.co.nz
www.vetassociates.co.nz

3. Veterinary Certificate

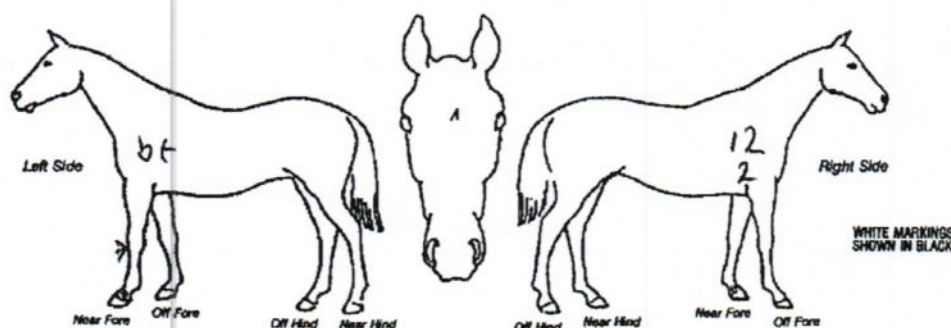
(a) Identification

Examining Veterinarian: I.S.Bridge.

Horse's Name: "CLIFTON GEM"

Description of horse said to be by Unknown out of Unknown.

COLOUR	BREED OR TYPE	SEX	AGE	APPROX HEIGHT
Bay.	Thoroughbred.	Gelding.	8yo	16.2hh.



Markings

Head and neck: No white markings.

Limbs
L.F. White half pastern.
R.F. No white markings.
L.H. No white markings.
R.H. No white markings.

Body

Brands: Left Shoulder bt.
Right Shoulder .. 12 over 2.

Certificate no. Page 1 of 3. Veterinary Certificate
Ivan Bridge B.V.Sc. Neil Houston B.V.Sc. M.A.C.V.Sc. Timm Gudehus Dr. Med. Vet. Rosemary Richards B.V.Sc. M.A.C.V.Sc.
Kelley Barrington B.V.Sc. M.A.C.V.Sc. Patrick O'Sullivan B.V.Sc. M.A.C.V.Sc.

EMERGENCY PHONE (09) 294 7307 (24 Hours)

(b) Veterinary Certificate

CAUTION This statement is provided upon the terms agreed to in the buyers statement and also those terms set out at the foot of the certificate of this report.

This is to certify that at the request of Mrs F.Stead (Buyer's Agent) I have examined the horse described above the property of Unknown at our Karaka Veterinary Hospital substantially in accordance with the standard procedure recommended by the Equine Branch of the New Zealand Veterinary Association.

Stages 1-5 of this standard procedure **were carried out**. The clinical findings and results of ancillary examinations and opinions have been detailed in the following report. This examination is carried out in five stages:

- Stage 1: Preliminary Examination.
- Stage 2: Examination during walking, trotting, turning and backing.
- Stage 3: Examination during and immediately after strenuous exercise.
- Stage 4: Examination in period after exercise.
- Stage 5: Examination during walking, trotting, turning and backing.

The recipient of this report is deemed to be aware that:-

1. Stages of the standard procedure recommended by the Equine Branch of the New Zealand Veterinary Association **have not been carried out** because of :-
2. Any information or opinion contained in this report is based on a partial examination only and some clinical signs of disease, injury or abnormality that may have manifested themselves in the full five stage examination may not be manifested if all stages (eg 1-5 previously described) of the examination have not been carried out.

Note: The provision of this certificate is subject to the various terms and conditions set out and in particular the disclaimers contained in Conditions (1) to (3) on page 4 of this certificate.

The following ancillary examinations were/were not carried out:

	Carried Out	Not Carried Out
Electrocardiographic Examination		x
Radiographic Examination (radiographs)	x	
Endoscopic Examination	x	
Reproductive Examination		x
Other Ancillary Examinations		x

Veterinary Clinical Findings and Opinion thereof:-

At the time of examination, the following observations were made:-

- The horse presented in good health and condition.
- Front feet were symmetric in size and shape with the left front measuring 15cm across the quarters and 8cm across the heels, they had a flattish sole conformation.
- The horse had a small wound on the dorsolateral aspect of the right hind cannon, this had apparently occurred in the truck whilst being transported to our hospital. It appeared relatively minor and was consistent with a strike from another horse, with proper care it would be expected to heal uneventfully.
- There was mild bursal thickening on the dorsal aspect of the left knee giving it visually a slightly different appearance to that of the right. This appeared well settled and of minor cosmetic significance only.
- There was what appeared to be a cataract observed in the right eye at the midline position with a horizontal slightly branched appearance. This cataract did not appear to be of present consequence but it has been arranged for Dr. Peter Collinson (eye specialist) to examine the horse tomorrow afternoon (28th January) and report his findings.
- Flexion tests were performed and response to these was normal.
- The horse was trotted on the lunge in 5m circles on a flat metal surface in both directions, no lameness was observed.
- The horse was ridden in our 30m sand arena, no lameness was observed and no abnormal respiratory noises were heard throughout this examination.

Radiographic Examination

Radiographs taken and read by I.S.Bridge.

Radiograph projections taken

Knees: Flexed lateromedial, skyline C3, dorsopalmar, dorsolateral-palmaromedial oblique and dorsomedial-palmarolateral oblique.

Front Fetlocks: Flexed lateromedial, lateromedial, dorsolateral-palmaromedial oblique, dorsomedial-palmarolateral oblique and dorsopalmar.

Front Pedal Bones: Lateromedial, dorsopalmar oblique.

Front Navicular Bones: Lateromedial, dorsopalmar, palmaroproximal-palmarodistal oblique.

Hocks: Lateromedial, dorsolateral-plantaromedial oblique, dorsomedial-plantarolateral oblique and dorsoplantar.

Radiographic Findings and Opinion Thereof:

- The left front fetlock radiographs showed the presence of a pointed osteophyte on the dorsolateral aspect of the 1st phalanx. There was only mild fetlock effusion observed, flexion produced a normal response and the horse trotted on a lunge in tight circles on a firm surface without issue. This radiographic finding in an 8yo horse would therefore not appear to be of current clinical significance. The significance to future usefulness is difficult to quantify but the horse presented with a history of consistent performance without issue over the last three years which would suggest moderate risk as being a fair appraisal.
- The left fetlock radiographs also showed a small rounded "divet" on the abaxial surface of the lateral sesamoid bone in the transitional zone. This finding in an adult horse would not be expected to carry risk to future athletic usefulness.
- The dorsolateral aspect of the 1st phalanx of the right fetlock showed a similar but much smaller osteophyte, again this did not appear of current clinical significance

Endoscopic Examination:

An endoscopic examination of the laryngo-pharyngeal area was carried out after work. No significant abnormalities were noted on this examination.

Further Conditions and disclaimers:

In addition to the terms and conditions set out in the buyer's statement you should also note that:-

- 1) On the advice of the Equine Branch of New Zealand Veterinary Association, no judgement is made about this horse's soundness, suitability for purchase or otherwise.
- 2) The certifying veterinarian takes no responsibility for, nor warrants the accuracy of, any information provided in the owner's statement, including that given relating to the non-administration of drugs, freedom from vice, pre-existing diseases or abnormalities, existing performance or suitability for intended use.
- 3) Where this examination and report are requested for the purpose of a business they are deemed to have been carried out upon the basis that the examining veterinarian's liability, howsoever arising, shall be no greater than a sum equivalent to 100 times the fee charged for the provision of this report. In addition, liability for consequential losses of any nature is also excluded.
- 4) This contract is governed by New Zealand law.
- 5) The Buyer/Buyer's Agent irrevocably agrees that the Courts of New Zealand will have exclusive jurisdiction to hear and determine all disputes under or in connection with this contract. The Buyer/Buyer's Agent further acknowledges that New Zealand is the forum conveniens for the hearing and determination for all disputes in connection with this contract.
- 6) Ownership of X-rays: The Buyer/Buyer's Agent acknowledges that any radiographs taken in the course of this examination are the property of the veterinary practice listed herein, but it is further acknowledged by the practice that copies of the radiographs will be supplied at the Buyer/Buyer's Agent's request and expense.
- 7) In addition, the nature and extent of this report has been determined by particular request. In the circumstances the examining veterinarian disclaims any liability whatsoever to any party other than the party directly responsible for requesting and paying for the services rendered.
- 8) Where an opinion has taken into consideration input from another professional, e.g. the taking and interpretation of radiographs, then in arriving at the opinion the veterinarian has accepted as accurate the information supplied.
- 9) Reliance upon this report will constitute an acceptance of the limitations of liability referred to above.

Date and time of examination: 27th January, 2011.

2.30am

Signed.....

Veterinarian and Qualifications I.S.Bridge. B.V.Sc.